


Microwave-Assisted Ablation Improves the Prognosis of Patients With Hepatocellular Carcinoma Undergoing Liver Resection

Technology in Cancer Research & Treatment
Volume 17: 1-6
© The Author(s) 2018
Reprints and permission:
sagepub.com/journalsPermissions.nav
DOI: 10.1177/1533033818785980
journals.sagepub.com/home/tct


Haiyuan Shen, MM¹ , Shu Zhou, MM¹, Yun Lou, MM¹, Yangjuan Gao, MM², Shouji Cao, MM¹, Du Wu, MM¹, and Guoqiang Li, MD¹

Abstract

Objective: We evaluated microwave-assisted liver resection for hepatocellular carcinoma. **Patients and Methods:** We enrolled 79 patients in this study, and microwave ablation was used for liver resection. Patients were randomized to group A (50.6%; n = 40), liver resection without microwave ablation, or group B (49.4%; n = 39), liver resection performed using microwave ablation. Data were analyzed for statistical significance. **Results:** Of the participants enrolled, 60 were male, and the participant's average age was 59.32 ± 10.34 years. The mean overall tumor diameter was 4.39 (2.00) cm, and this did not differ between groups. Intraoperative blood loss in group B was significantly less than that in group A ($P < .001$). No differences were reported between the 2 groups regarding surgical time ($P = .914$), postoperative morbidity ($P = .718$), and late postoperative complications ($P = .409$). Postoperative drainage volume for group B was less than that of group A on the first ($P = .005$) and third ($P = .019$) day after surgery. The time of postoperative hospitalization in group B was significantly shorter than that in group A ($P < .001$). Local recurrence was noted in 18.99% of cases (n = 15) in group B, which is less than that of group A ($P = 0.047$), while in group B distant metastasis is less but not statistically significant ($P = 0.061$). The 1-year and 3-year cumulative survival rates were 57% and 93.7%, respectively. **Conclusions:** The curative effects of liver resection combined with microwave ablation during operation are superior to only liver resection in the treatment of primary liver cancer.

Keywords

thermal ablation, bloodless hepatectomy, primary liver cancer, liver resection, prognosis

Abbreviations

AFP, alpha fetoprotein; ALT, alanine aminotransferase; AST, aspartate aminotransferase; HCC, hepatocellular carcinoma; MW, microwave; MWA, microwave ablation; PT, prothrombin time; TB, total bilirubin

Received: December 10, 2017; Revised: March 14, 2018; Accepted: May 30, 2018.

Introduction

Hepatocellular carcinoma (HCC) is a common malignant tumor, the fifth most common cancer worldwide for men and the ninth most frequent cancer for women.¹ Hepatocellular carcinoma is associated with high mortality and poor prognosis, causing 500 000 deaths annually.²⁻⁴ Hepatocellular carcinoma is more common in Asia and Africa, but its incidence has increased over the last several decades in Western countries.⁵

Although liver resection and transplantation are the most effective means for treating HCC, these procedures are suitable only for <20% of patients due to a high risk of intraoperative blood loss and perioperative transfusions, which directly

influence postoperative morbidity and mortality.⁶⁻⁹ To improve the safety of surgery, more secure techniques have been developed.¹⁰⁻¹⁵ Local tumor thermal ablation allows fast

¹ Department of Liver Surgery, The First Affiliated Hospital of Nanjing Medical University, Nanjing, Jiangsu Province, China

² Department of Radiology, The First Affiliated Hospital of Nanjing Medical University, Nanjing, Jiangsu Province, China

Corresponding Author:

Guoqiang Li, MD, Department of Liver Surgery, The First Affiliated Hospital of Nanjing Medical University, Nanjing, Jiangsu Province, China.
Email: liguoqiang@njmu.edu.cn



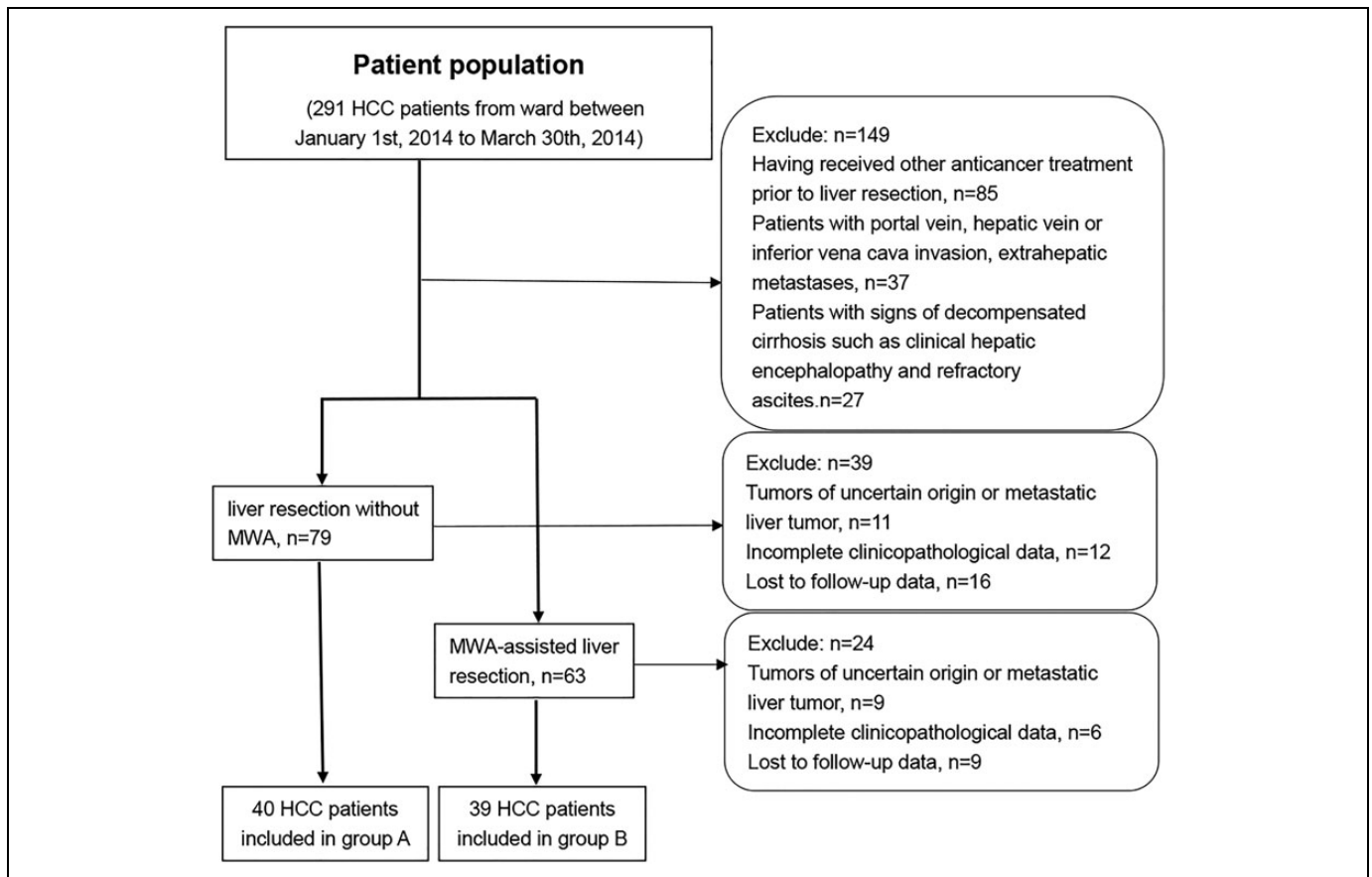


Figure 1. Flowchart of patient enrollment.

heating, partial inactivation tissue, less trauma, and fewer complications.^{16,17} Moreover, thermal-assisted liver resection is also virtually bloodless.¹⁸

Microwave ablation (MWA), a new thermal ablation approach which was introduced in the 1990s, has emerged as a promising, minimally invasive treatment option. Microwave (MW) can deliver relatively high temperature into the tumor over a short time and cover a large ablation zone, which can improve ablation efficiency with less cardiovascular events.¹⁹ Recently, it has been thought that MWA may be a valuable alternative method for treating hepatic disease.²⁰ One randomized study showed that MWA was equally effective as surgery for treating hepatic metastases.²¹

Microwave ablation is gaining acceptance for local therapy due to its demonstrable clinical benefits. Thus, we evaluated the effect of an approach to combining MWA and liver resection for HCC. The primary measurable outcomes were intraoperative blood loss and postoperative recovery index. We also analyzed the length of hospital stay, postoperative morbidity, and survival time.

Patients and Methods

Patient Enrollment

We enrolled 79 patients who underwent liver resection for HCC at the Liver Transplantation Center of the First Affiliated

Hospital of Nanjing Medical University from January 1, 2014, to March 30, 2014. Patients were randomized to group A, liver resection without MWA ($n = 40$), or group B, MWA-assisted liver resection ($n = 39$). The flowchart of patient enrollment of this study is shown in Figure 1.

Patient inclusion criteria are as follows: (1) surgical specimens with confirmed HCC; (2) total number of tumor lesions ≤ 3 ; (3) largest single tumor diameter ≤ 10 cm; (4) for patients with multiple tumors (2 or 3), no more than one lesion > 5 cm; (5) Child-Pugh score A or B; (6) no distant metastasis; and (7) no MWA treatment contraindications.

Patient exclusion criteria are as follows: (1) incomplete clinic pathological data; (2) patients who received anticancer treatment before surgery, such as hepatic resection, sorafenib, radiofrequency ablation, or transcatheter arterial chemoembolization; (3) patients with portal vein, hepatic vein or inferior vena cava invasion, extrahepatic metastases, or malignancies of other tissue of origin; (4) patients with signs of decompensated cirrhosis such as clinical hepatic encephalopathy and refractory ascites; and (5) lost to follow-up.

Ethics committee of the First Affiliated Hospital of Nanjing Medical University (approval number: 2013-SR-092) approved the study. Informed consents from patients to allow the review and analyses of their medical records were obtained.

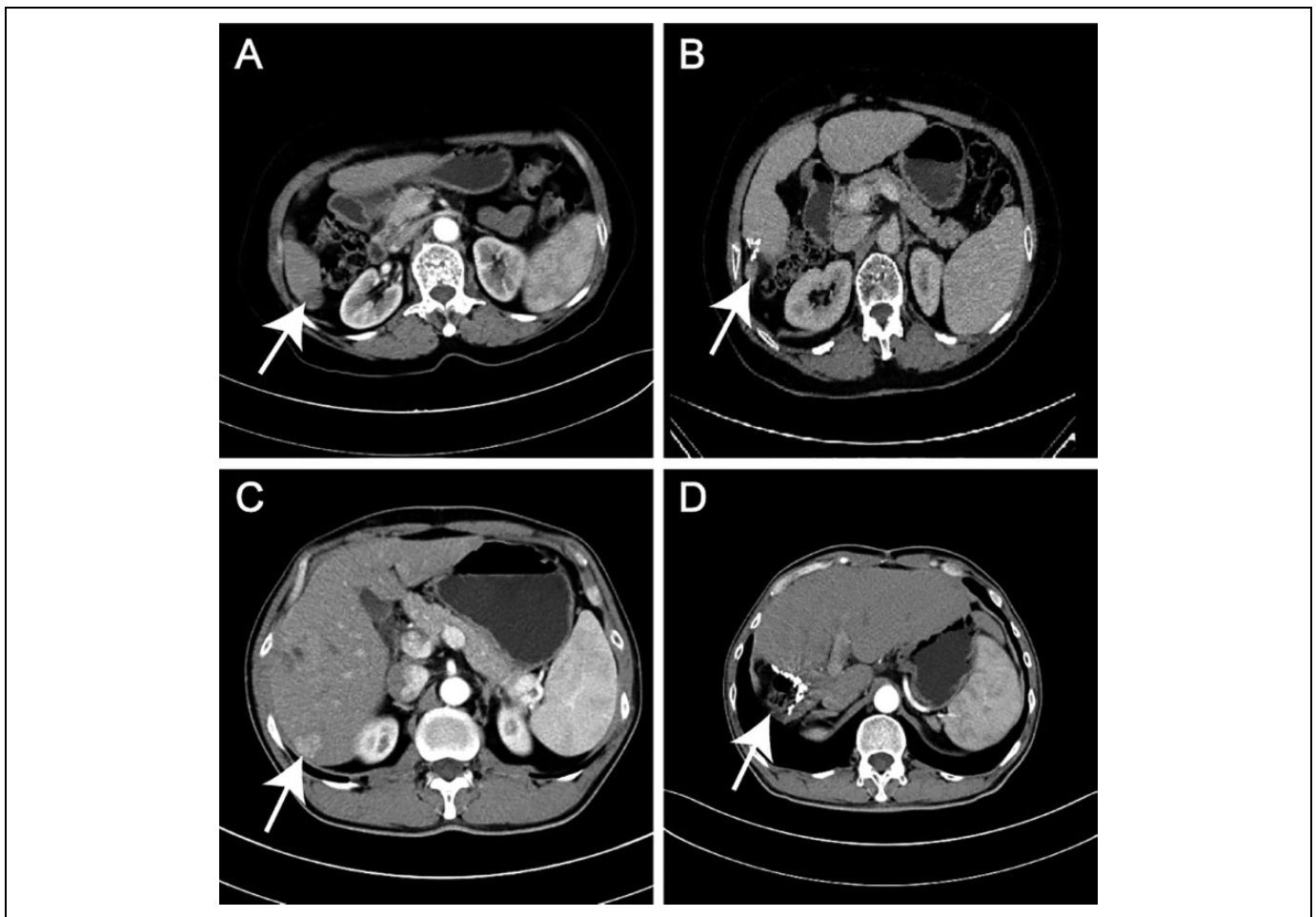


Figure 2. A, Perioperative contrast-enhancement CT showing a tumor of approximately 2×2 cm (a 65-year-old female patient with HCC). B, Follow-up CT 6 months after liver resection without MWA. C, Perioperative contrast-enhancement CT showing a tumor of approximately 3.6×3 cm (a 50-year-old male patient with HCC). D, Follow-up CT 6 months after MWA-assisted liver resection. CT indicates computed tomography; HCC, hepatocellular carcinoma; MWA, microwave ablation.

Surgical Procedure

All surgical procedures were performed by skilled surgical teams. For group A, local hepatectomy or regular hepatectomy of left or right lobe was performed according to tumor size and location. Group B was treated with MWA before resection. Microwave ablation was performed at the scheduled resection plane, and the surgical electrode needle was punctured into the side of the tumor at the plane and then gradually pushed forward, overlapping many times, to cover the entire resection plane. Then, conventional hepatectomy was performed. A 100 ECO MWA device (Nanjing YiGao Engineering Co Ltd, Jiangsu, China) was used at a frequency of 2450 MHz and a maximum output power of 100 W. There was a 16-G insulation antisticking puncture guide needle for tumor puncture into the MW electrode and insulation of the implanted MW antenna (Figure 2).

Data Analysis

Demographic, clinical, imaging, biological, and surgical data were analyzed. Lab tests (eg, alanine aminotransferase [ALT],

aspartate aminotransferase [AST], albumin, total bilirubin [TB], prothrombin time [PT], and alpha fetoprotein [AFP]) were performed preoperatively and 7 days after surgery. Patients were assessed using the Child-Pugh classification and Model for End-Stage Liver Disease scores. Tumor volume was estimated by computed tomography volumetric computing. Surgical time and blood loss were recorded and analyzed. Blood transfusion was performed when hemoglobin decreased to below 8 g/dL or blood loss during surgery was above 400 mL. Resected specimens were analyzed histopathologically to confirm their status. Postoperative median follow-up was 18 months (range: 7-40 months). Tumor recurrence, metastasis, and mortality were also recorded. Deaths occurring within postoperative 30 days were referred to as postoperative mortality.

Statistical Analysis

All data were encoded and analyzed using SPSS 19.0 statistical software. Data from both groups are presented as numbers and

Table 1. Demographic and Clinical Data.

Characteristics	Group A (n = 40)	Group B (n = 39)	P Value
Age (>55 years)	28 (70.0%)	21 (53.8%)	.138
BMI (>24)	15 (37.5%)	12 (30.8%)	.528
Sex (male/female)	29 (72.5%)/11 (27.5%)	31 (79.5%)/8 (20.5%)	.467
Smoke	9 (22.5%)	10 (25.6%)	.744
Alcohol	6 (15.0%)	6 (15.4%)	.962
Diabetes	4 (10.0%)	5 (12.8%)	.693
Hypertension	9 (22.5%)	8 (20.5%)	.830
HBV	24 (60.0%)	24 (61.5%)	.889
Liver cirrhosis	26 (65.0%)	24 (61.5%)	.750
Child-Pugh class			
Child A	22 (90.9%)	22 (91.7%)	.900
Child B	4 (10.0%)	2 (8.3%)	.409
Symptomatic HCC	36 (90.0%)	33 (84.6%)	.471

Abbreviations: BMI, body mass index; HBV, Hepatitis B Virus; HCC, hepatocellular carcinoma.

percentages. Descriptive and bivariate statistics (Student *t* test, Pearson χ^2 , and Cox regression analyses) were used. Data are means (standard deviation). Survival time was computed using the Kaplan-Meier function. For analyses, $P < .05$ indicated statistical significance.

Results

Clinical demographics of all patients are summarized in Table 1. Preoperative and postoperative biological data including AFP level and liver function tests (serum albumin, ALT, AST, TB, and PT) are summarized in Table 2. There was no significant difference between these 2 groups. Operative risks and postoperative complications are summarized and assessed in Table 3. Cases of blood loss above 200 mL were significantly less in group B than that in group A ($P < .001$). There was no significant difference in surgical time and blood transfusion between these 2 groups.

All patients in both groups were discharged, and there were no deaths or serious complications during the perioperative period. However, the hospital stay of above 10 days in group A was significantly longer than that in group B ($P < .001$). Postoperative drainage volume in group B was less than that in group A on the first ($P = .005$) and third ($P = .019$) day after surgery. Both groups had similar postoperative morbidity and late postoperative morbidity (eg, chronic liver failure, ascites, and postoperative incision hernias). Local recurrence of HCC was significantly lower in group B ($P = .047$); however, distant metastases in lungs and bones were found in 9 and 3 patients, respectively, in groups A and B, which was not significant ($P = .061$).

The 1-year and 3-year survival rates were 93.7% and 57.0%, respectively. The 3-year survival rate of group A (47.5%) was lower than that of group B (66.7%; Figure 3B), and differences are statistically significant ($P = .044$). There was a difference in follow-up time between the 2 groups.

Table 2. Preoperative and 7 Days Postoperative Biological Data.

Characteristics	Group A (n = 40)	Group B (n = 39)	P Value
AFP (>400 $\mu\text{g/L}$)	34 (85.0%)	30 (76.9%)	.359
Albumin (>35 mg/dL) preoperative	20 (50.0%)	20 (51.3%)	.909
Albumin (>35 mg/dL) postoperative	25 (62.5%)	25 (64.1%)	.883
ALT (>40 U/L) preoperative	40 (100%)	39 (100%)	1.000
ALT (>40 U/L) postoperative	28 (70.0%)	26 (66.7%)	.750
AST (>40 U/L) preoperative	40 (100%)	39 (100%)	1.000
AST (>40 U/L) postoperative	10 (25.0%)	9 (23.1%)	.841
TBIL (>25 $\mu\text{mol/L}$) preoperative	11 (27.5%)	7 (17.9%)	.310
TBIL (>25 $\mu\text{mol/L}$) postoperative	5 (12.5%)	6 (15.4%)	.711
PT (>14 seconds) preoperative	2 (5.0%)	1 (2.6%)	.567
PT (>14 seconds) postoperative	11 (27.5%)	8 (20.5%)	.467

Abbreviations: AFP, alpha fetoprotein; AST, aspartate amino transferase; ALT, alanine amino transferase; PT, prothrombin time; TBIL, total bilirubin.

Table 3. Operative and Postoperative Data.

Characteristics	Group A (n = 40)	Group B (n = 39)	P Value
Operation time (>180 minutes)	19 (47.5%)	19 (48.7%)	.914
Tumor diameter			
<3 cm	3 (7.5%)	10 (25.6%)	0.026
3-5 cm	20 (50.0%)	18 (46.2%)	.732
>5 cm	17 (42.5%)	11 (28.2%)	.183
Multiple tumors	4 (10.0%)	5 (12.8%)	.693
Blood loss (>200 mL)	28 (70.0%)	10 (25.6%)	.000
Blood transfusion	11 (27.5%)	10 (25.6%)	.852
Drainage day 1 (>100 mL)	19 (47.5%)	7 (17.9%)	.005
Drainage day 3 (>100 mL)	18 (45.0%)	8 (20.5%)	.019
Drainage day 7 (>100 mL)	9 (22.5%)	5 (12.8%)	.257
Pyrexia	12 (30.0%)	8 (20.5%)	.331
Complications	4 (10.0%)	3 (7.7%)	.718
Postoperative hospital stay			
>10 days	33 (82.5%)	13 (33.3%)	.000
Cost (>\$7000)	24 (60.0%)	28 (71.8%)	.268
Late postoperative morbidity	4 (10.0%)	2 (5.1%)	.409
Recurrence	11 (27.5%)	4 (10.2%)	.047
Metastasis	9 (22.5%)	3 (7.7%)	.061

Discussion

Surgery is the primary treatment for patients with HCC, and traditional liver resection which brings much trauma affects prognosis and recovery of patients. Partial hepatectomy is the main treatment for patients with HCC, but for those with a high risk of recurrence, auxiliary MWA may be used to reduce recurrence.²²⁻²⁴

One randomized study showed that MWA was equally effective as surgery for treating hepatic metastases,²¹ and research suggests that thermal ablation therapy is useful²⁵; however, the long-term surgical effects of this approach have not been well studied.²⁶ We report that average blood loss was significantly less in MWA-assisted group, and postoperative drainage of the study group was less than that of controls too. Postoperative hospitalization time was significantly shorter in

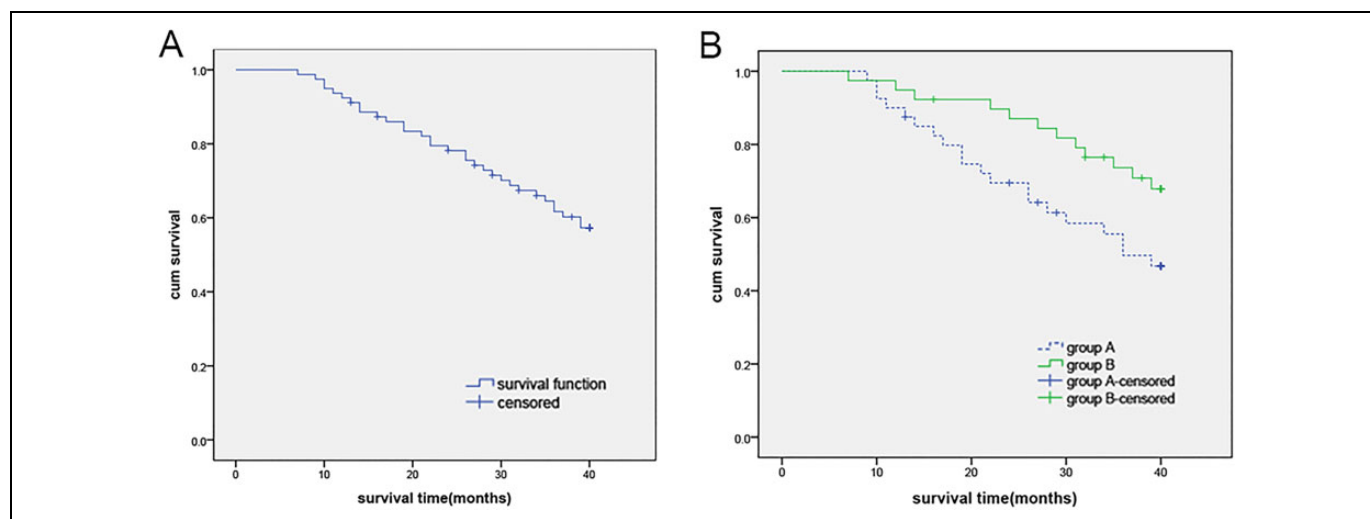


Figure 3. A, Overall survival time. B, Survival time in the 2 groups (Kaplan-Meier).

the MWA-assisted group, and after 3 years of follow-up, the survival rate of MWA-assisted group was significantly greater than that of the liver resection group, which suggests that MWA-assisted partial liver resection for HCC is beneficial. Conventional partial hepatectomy requires repeated hepatic portal occlusion, which can control bleeding, but is limited and may lead to hepatic ischemia–reperfusion injury; this can be injurious to patients with liver cirrhosis^{14,27} and cause liver dysfunction or failure.

Group B was treated with MWA with conventional surgical resection and friction, and heat produced by MWA caused cellular death via coagulation necrosis.^{12,28} This created local tissue protein coagulation and necrosis and was effective for reducing tumor cells along cancer margins as well as inducing hemostasis, which contributed to bloodless hepatectomy. Better recovery after MWA was also noted due to complete hemostasis, and postoperative drainage was significantly reduced, which reduced the length of hospital stay.

Microwave ablation is a well-known technique in the treatment of hepatic malignant tumors to show low incidence of postoperative complications.²⁹ According to a large-scale multicenter study over 13 years, complications occurred in 2.9% of patients,³⁰ including bile duct injury, bleeding artery embolization, hepatic abscess and empyema, colonic perforation, skin burns, and tumor transplantation. Fever was one of the common side effects, and more than 83.4% of patients had fever for 24 to 48 hours after surgery.³¹

Thermal ablation therapy assisted liver resection by which coagulated liver parenchyma “seals” the tumor.^{32–34} Overall survival for liver resection with and without MWA is 40% for both groups after 3 years^{35–36} in the literature, and our data are similar. In particular, survival for both groups after 1 year was 90.0% and 97.4%, respectively, and survival for group B after 3 years was higher than that of group A. This may be due to more patients with small HCC in group B. This study is limited by

the small number of cases, its observational nature, and the shorter follow-up time.

Conclusions

Microwave ablation–assisted liver resection is a feasible and safe procedure for the treatment of HCC and allows liver resection with lower metastasis and recurrence rate. Blood loss was less when compared to conventional procedures, and the patients recovered faster with shorter hospital stays.


Declaration of Conflicting Interests

The author(s) declared no potential conflicts of interest with respect to the research, authorship, and/or publication of this article.

Funding

The author(s) received no financial support for the research, authorship, and/or publication of this article.

ORCID iD

Haiyuan Shen  <http://orcid.org/0000-0003-3520-8402>

References

1. Ferlay J, Soerjomataram I, Dikshit R, et al. Cancer incidence and mortality worldwide: sources, methods and major patterns in GLOBOCAN 2012. *Int J Cancer*. 2015;136(5):E359–E386.
2. Bang JS, Kim SH, Yang SH. Ileal perforation with diaphragmatic injury after radiofrequency ablation for hepatocellular carcinoma. *Turk J Gastroenterol*. 2016;27(2):202–204.
3. Kassi AB, Beuvon F, Costi R, Massault PP, Dousset B. Parietal seeding of HCC after percutaneous radiofrequency thermal ablation. *Rev Med Brux*. 2016;37(2):114–115.
4. Li L, Zhang J, Liu X, Li X, Jiao B, Kang T. Clinical outcomes of radiofrequency ablation and surgical resection for small hepatocellular carcinoma: a meta-analysis. *J Gastroenterol Hepatol*. 2012;27(1):51–58.

5. Venook AP, Papandreou C, Furuse J, de Guevara LL. The incidence and epidemiology of hepatocellular carcinoma: a global and regional perspective. *Oncologist*. 2010;15(suppl 4):5-13.
6. Kudo M. Hepatocellular carcinoma 2009 and beyond: from the surveillance to molecular targeted therapy. *Oncology*. 2008;75(suppl 1):1-12.
7. Sugawara Y, Inomata Y. Indications for living donor liver transplantation in patients with hepatocellular carcinoma. *Hepatobiliary Surg Nutr*. 2016;5(5):429-432.
8. Lai EC, Fan ST, Lo CM, Chu KM, Liu CL, Wong J. Hepatic resection for hepatocellular carcinoma. An audit of 343 patients. *Ann Surg*. 1995;221(3):291-298.
9. Kooby DA, Stockman J, Ben-Porat L, et al. Influence of transfusion on perioperative and long-term outcome in patients following hepatic resection for colorectal metastases. *Ann Surg*. 2003;237(6):860-869.
10. Sugo H, Mikami Y, Matsumoto F, et al. Hepatic resection using the harmonic scalpel. *Surg Today*. 2000;30(10):959-962.
11. Sakamoto Y, Yamamoto J, Kokudo N, et al. Bloodless liver resection using the monopolar floating ball plus ligasure diathermy: preliminary results of 16 liver resections. *World J Surg*. 2004;28(2):166-172.
12. Yamada T, Sasaki Y, Yokoyama S, et al. Practical usefulness of bipolar scissors in hepatectomy. *Hepato Gastroenterol*. 2002;49(45):597-600.
13. Takayama T, Makuuchi M, Kubota K, et al. Randomized comparison of ultrasonic vs clamp transection of the liver. *Arch Surg*. 2001;136(8):922-928.
14. Weber JC, Navarra G, Jiao LR, Nicholls JP, Jensen SL, Habib NA. New technique for liver resection using heat coagulative necrosis. *Ann Surg*. 2002;236(5):560-563.
15. Bruix J, Sherman M; American Association for the Study of Liver Diseases. Management of hepatocellular carcinoma: an update. *Hepatology*. 2011;53(3):1020-1022.
16. Chu KF, Dupuy DE. Thermal ablation of tumors: biological mechanisms and advances in therapy. *Nat Rev Cancer*. 2014;14(3):199-208.
17. Yi Y, Zhang Y, Wei Q, et al. Radio frequency ablation or microwave ablation combined with transcatheter arterial chemoembolization in treatment of hepatocellular carcinoma by comparing with radiofrequency ablation alone. *Chin J Cancer Res*. 2014;26(1):112-118.
18. Ayav A, Jiao LR, Habib NA. Bloodless liver resection using radiofrequency energy. *Dig Surg*. 2007;24(4):314-317.
19. Wu W, Xue Y, Wang D, Xue J, Zhai W, Liang P. A simulator for percutaneous hepatic microwave thermal ablation under ultrasound guidance. *Int J Hyperthermia*. 2014;30(7):429-437.
20. Yu J, Liang P, Yu X, Liu F, Chen L, Wang Y. A comparison of microwave ablation and bipolar radiofrequency ablation both with an internally cooled probe: results in ex vivo and in vivo porcine livers. *Eur J Radiol*. 2011;79(1):124-130.
21. Shibata T, Niinobu T, Ogata N, et al. Microwave coagulation therapy for multiple hepatic metastases from colorectal carcinoma. *Cancer*. 2000;89(2):276-284.
22. Mabrut JY, Ducerf C. Surgical management of hepatocellular carcinoma in 2010. *Cancer Radiother*. 2011;15(1):13-20.
23. Llovet JM, Burroughs A, Bruix J. Hepatocellular carcinoma. *Lancet*. 2003;362(9399):1907-1917.
24. Bruix J, Hessheimer AJ, Forner A, Boix L, Vilana R, Llovet JM. New aspects of diagnosis and therapy of hepatocellular carcinoma. *Oncogene*. 2006;25(27):3848-3856.
25. Forner A, Llovet JM, Bruix J. Hepatocellular carcinoma. *Lancet*. 2012;379(9822):1245-1255.
26. Curro G, Habib N, Jiao L, Baccarani U, Scisca C, Navarra G. Radiofrequency-assisted liver resection in patients with hepatocellular carcinoma and cirrhosis: preliminary results. *Transplant Proc*. 2008;40(10):3523-3525.
27. Curro G, Jiao L, Scisca C, et al. Radiofrequency-assisted liver resection in cirrhotic patients with hepatocellular carcinoma. *J Surg Oncol*. 2008;98(6):407-410.
28. Brace CL. Radiofrequency and microwave ablation of the liver, lung, kidney, and bone: what are the differences? *Curr Probl Diagn Radiol*. 2009;38(3):135-143.
29. Lahat E, Eshkenazy R, Zendel A, et al. Complications after percutaneous ablation of liver tumors: a systematic review. *Hepatobiliary Surg Nutr*. 2015;3(5):317-323.
30. Livraghi T, Meloni F, Solbiati L, et al. Complications of microwave ablation for liver tumors: results of a multicenter study. *Cardiovasc Intervent Radiol*. 2012;35(4):868-874.
31. Tang XY, Wang Z, Wang T, Cui D, Zhai B. Efficacy, safety and feasibility of ultrasound-guided percutaneous microwave ablation for large hepatic hemangioma. *J Dig Dis*. 2015;16(9):525-530.
32. Tarcoveanu E, Moldovanu R, Lupascu C. Hepatic resection using focal destruction procedures. *J Chir (Iasi)*. 2007;3(4):378-383.
33. Târcoveanu E, Eloae FZ, Lupaşcu C, et al. Thermo-necrosis in nonresectable colorectal hepatic malignant tumors. Preliminary results [in Romanian]. *Rev Med Chir Soc Med Nat Iasi*. 2007;111(1):161-74.
34. Târcoveanu E, Lupaşcu C, Moldovanu R, et al. La thermonecrose avec des vapeurs surchauffees dans le traitement des metastases hepatiques ducancer colorectal. Paper presented at: Session Scientifique Commune; Academie Nationale de Medecine de France, Union Medicale Balkanique, Academie des Sciences de Roumanie; Paris, September 28-29, 2009.
35. Belghiti J, Regimbeau JM, Durand F, et al. Resection of hepatocellular carcinoma: a European experience on 328 cases. *Hepatogastroenterology*. 2002;49(43):41-46.
36. Ercolani G, Grazi GL, Ravaioli M, et al. Liver resection for hepatocellular carcinoma on cirrhosis: univariate and multivariate analysis of risk factors for intrahepatic recurrence. *Ann Surg*. 2003;237(4):536-543.